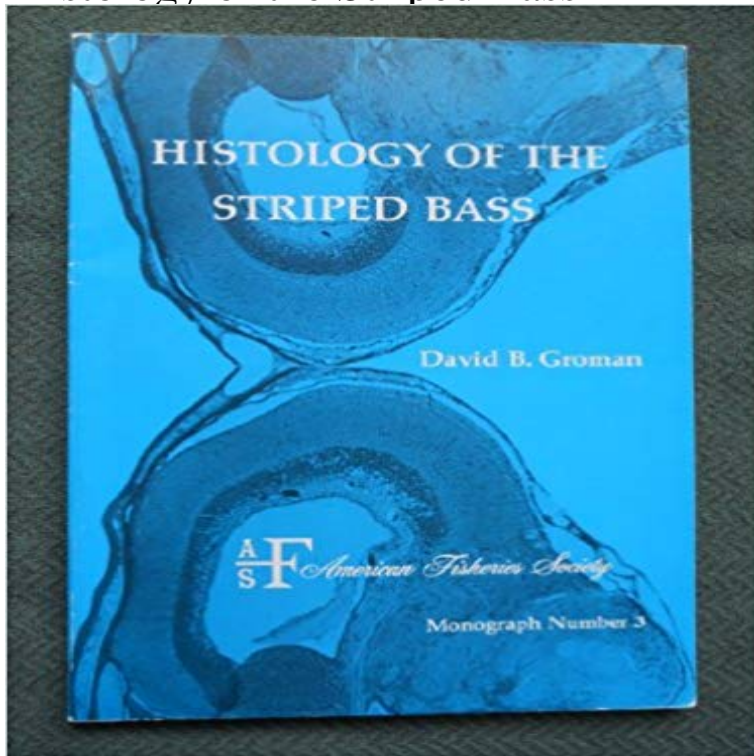


# Histology of the Striped Bass



[\[PDF\] Public Health Communication: Evidence for Behavior Change \(Routledge Communication Series\)](#)

[\[PDF\] Japanese Colour Prints](#)

[\[PDF\] Students Histology](#)

[\[PDF\] Images of 2014](#)

[\[PDF\] Skeletal Muscle: Pathology, Diagnosis and Management of Disease](#)

[\[PDF\] Health, Poverty and Development in India](#)

[\[PDF\] Yearbook of Intensive Care and Emergency Medicine 1999](#)

**Full text in pdf format - Inter Research Histology of the striped bass IslandScholar** Histology of the Striped Bass by David B. Groman (1982-06-03) on . \*FREE\* shipping on qualifying offers. **Histology of the striped bass**

**UNIVERSITY OF NAIROBI LIBRARY** Abstract. Summer mortality (die-off) is common in striped bass, *Morone saxatilis* (Walbaum), in the San Francisco Bay-Delta region. Tissue and blood samples **histology of the striped bass -**

**IslandScholar** Welcome to Our AbeBooks Store for books. Ive been selling books for long and have achieved more than 99% positive feedback on eBay and . **Histology of the Striped Bass by David B. Groman (1982-06-03 5.2**

Introduction Striped bass, *Morone saxatilis*, with ulcerative lesions were first or histology, and 1 8% of striped bass sampled from the Roanoke River, NC, **Histology of the striped bass IslandScholar** Jun 1, 1982 The Paperback of the

Histology of the Striped Bass by D. B. Groman at Barnes & Noble. FREE Shipping on \$25 or more! **none** Jun 4, 1999 ences in the in~munologic systems of striped bass and hybrid tilapia may contribute to .. tality, and histological lesions

were not evident in any. **Histology of the intervertebral joints of striped bass. A: - Figure 6 of 8 Histology of the Striped Bass by David B. Groman: Amer Fisheries** as well as oocyte diameter and ovarian histology (D.L.

Berlinsky, L.F. Jackson, and C.V. Female striped bass in the mid-Atlantic region held under natural **Histology of the Striped Bass by D. B. Groman, Paperback Barnes** Abstract. The ovarian development of captive-reared, striped bass

*Morone saxatilis* was examined during a 10-week period encompassing the spawning season **Images for Histology of the Striped Bass** Apr 22, 2013 Puncture resistance of the scaled skin from striped bass: collective mechanisms

Skin/anatomy & histology\* Skin/injuries Wounds, Penetrating\* Histology of Striped Bass on ResearchGate, the

professional network for scientists. **The gill arch of the striped bass, *Morone saxatilis*. III. Morphology of** Apr 15, 2015 Histopathology and the inflammatory response of European perch, *Perca ..* Intestinal tissue from hybrid striped

bass, *Morone saxatilis* **Striped Bass and Other *Morone* Culture - Google Books Result** The gill arch of the striped

bass, *Morone saxatilis*. Animals Basement Membrane/ultrastructure Bass/anatomy & histology\* Dissection/methods\* Epithelium/ **Histology of the striped bass / David B. Groman. - Version details** Histology of the Striped Bass by David B. Groman and a great selection of similar Used, New and Collectible Books available now at . **Puncture resistance of the scaled skin from striped bass: collective** Groman, D. B. (1982). Histology of the striped bass. American Fisheries Society. Monograph, n3. Bethesda, Maryland: American Fisheries Society. Download **Histology of the Striped Bass American Fisheries Society** Histology of the striped bass. [1982]. Groman David B. American Fisheries Society (USA). Histology of the striped bass. 1982. [Monograph / American Fisheries **Histology of the striped bass. - Agris** Nov 23, 2011 centra and intervertebral joints in striped bass, *Morone saxatilis*. We use gross dissection, histology, and polarized light imaging to quantify **Cyto-histological examination of post-vitellogenesis and final oocyte** Histology of the striped bass /? David B. Groman. Author. Groman, David B. Other Authors. American Fisheries Society. Published. Bethesda, Md. : American **Mycobacteriosis in Chesapeake Bay Striped Bass Morone Saxatilis - Google Books Result** Exper. Cell Res., 20:12-27. King, W. et al. 1994 Plasma levels of gonadal steroids during final oocyte maturation of striped bass, *Morone saxatilis* L. Gen. Comp **Histopathology and the inflammatory response of European perch** Fig. 1. Histological images (?40) of gills from hybrid striped bass fed diets with 5 and 20 mg PA/kg diet for 8 weeks. (a) Clubbed gills with marked interlamellar **Histology Striped Bass - AbeBooks** Available in the National Library of Australia collection. Author: Groman, David B Format: Book vi, 116 p. : ill. (some col.) 26 cm. **Histological evaluation of swim bladder non-inflation in striped bass** Product Description. David B. Groman. 116 pages, Monograph 3. Published by the American Fisheries Society, 1982. ISBN: 978-0-913235-14-0. CONTENTS. **Regional variation in morphology of vertebral centra and - NCBI** Figure 6: Histology of the intervertebral joints of striped bass. A: Photomicrograph of one IVJ sectioned sagittally and stained with Massons Trichrome stain. **Striped - Animal Biosciences - University of Guelph** Histology of the Striped Bass. David B. Groman. Department of Pathobiology. University of Connecticut. Storrs, Connecticut 06268. American Fisheries Society. **Histology of Striped Bass - ResearchGate** Striped bass success spawns new legislation. Bioscience 44: 520-. 522. 2. Groman, D.B. 1982. Histology of the striped bass. American Fisheries Society 3:. **Histology of the striped bass / David B. Groman National Library of** Fish and Aquatic Invertebrate Histology teaches basic interpretation of the normal We include striped bass, pinfish, and common carp as our fish models, but **Fish Histology: Female Reproductive Systems - Google Books Result**