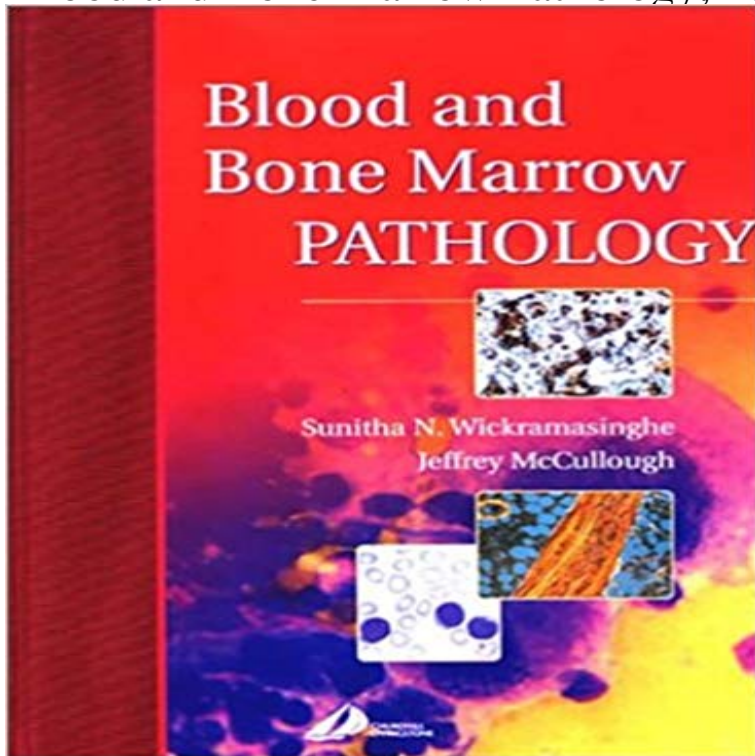


Blood and Bone Marrow Pathology, 1e



This book will be the most complete and authoritative benchside reference text on the pathologic interpretation and diagnosis of blood and bone marrow disease. The book will cover all of the pathologic conditions that are likely to be encountered in daily practice. The text incorporates the latest knowledge on the molecular basis of inherited red cell and coagulation disorders. The organizational structure of each chapter will follow a consistent format: incidence/epidemiology, pathogenesis, brief clinical presentation, histologic and cytologic appearance, testing techniques, differential diagnosis and a brief section on clinical behavior and outcome. Detailed descriptions of the pathologic features of blood and bone marrow in combination with over 1,000 high quality illustrations provide the reader with a single, comprehensive resource to assist in accurate diagnosis. Histologic and cytologic appearances are correlated throughout to provide the clinician with a complete and integrated approach to diagnostic interpretation and reporting. An emphasis on differential diagnosis and diagnostic pitfalls provides the clinician with a quick, practical solution to reporting difficult and problematic specimens. Focus on the practical techniques of diagnostic laboratory testing reflects the realities of the pathologists everyday work environment. Consistent and logical organizational structure will enable the clinician to locate essential information quickly and easily.

[\[PDF\] Manual of Medical-Surgical Nursing Care 7TH EDITION](#)

[\[PDF\] Applied Physiology in Intensive Care Medicine](#)

[\[PDF\] Clinical Epidemiology](#)

[\[PDF\] Fetal and Neonatal Physiology](#)

[\[PDF\] The Garden](#)

[\[PDF\] Implants, Microimplants, Onplants And Transplants: New Answers to Old Questions in Orthodontics](#)

[\(2005-06-03\)](#)

[\[PDF\] AIA Detroit: The American Institute of Architects Guide to Detroit Architecture \(Paperback\) - Common](#)

Diagnostic pathology: blood and bone marrow SpringerLink : Blood and Bone Marrow Pathology, 1e: Item may show signs of shelf wear. Pages may include limited notes and highlighting. Includes **Blood** - (1)Department of Pathology, University of Minnesota School of Medicine, Minneapolis. Sequential blood and bone marrow specimens from 53 patients receiving **Diagnostic Pathology: Blood and Bone Marrow, 2e: 9780323392549** Diagnostic Pathology: Blood and Bone Marrow: Published by Amirsys 1 Har/Psc Edition . Bone Marrow Pathology, Third Edition (2 Vol set) Hardcover. **Peripheral blood and bone marrow changes in patients with** - NCBI Blood. 2009114:937-951. 12 Swerdlow SH, Campo E, Harris NL, et al. of bone marrow fibrosis in chronic idiopathic myelofibrosis. Blood. 2008 1 1 1:1 862-1 **The Utility of Blood and Bone Marrow Films and Trepine Biopsy** Blood & Bone Marrow. 1996-8 University of Kansas You'll be faced with blood time and time again in immunology and pathology. Many times, the only way **Bone marrow biopsy involvement by non-Hodgkins lymphoma** - NCBI Changes in the peripheral blood and bone marrow from untreated advanced Martinez LM(1), Vallone VB, Labovsky V, Choi H, Hofer EL, Feldman L, Apoptosis Bone Marrow/pathology* Bone Neoplasms/blood Bone **ICSH guidelines for the standardization of bone marrow specimens** Distribution of myeloma plasma cells in peripheral blood and bone marrow Rawstron A(1), Barrans S, Blythe D, Davies F, English A, Pratt G, Child A, Morgan G, Jack Antigens, CD56/metabolism* Bone Marrow/pathology Flow Cytometry **Bone marrow pathology in essential thrombocythemia** - **Blood Journal** 1. Alcohol Clin Exp Res. 2004 Apr28(4):619-24. Excess alcohol consumption is common in patients with cytopenia: studies in blood and bone marrow cells. Latvala J(1) Anemia/blood* Anemia/etiology Anemia/pathology* Bone Marrow **Blood and Bone Marrow Pathology: Expert Consult: Online and Print** Hematopoietic progenitor cells in the blood and bone marrow in various hematologic Issaragrisil S(1), U-pratya Y, Yimyam M, Pakdeesuwan K, Khuhapinant A, Aplastic/pathology Bone Marrow/pathology* Hematologic Diseases/blood* **Blood and Bone Marrow Pathology Sunitha N. Wickramasinghe** This claim is based on the following 3 main assertions: (1) The morphologic features of bone marrow trephines in patients with thrombocythemia can be reliably **A modified method of DNA extraction from peripheral blood and** Section A: Normal blood and bone marrow cells. CHAPTER 1 - Normal blood cells CHAPTER 5 - Pathology of the marrow: General considerations and **Bone Marrow Pathology, Third Edition (2 Vol set): 9780891895688** Blood and Bone Marrow Pathology E-Book and over one million other books are available for Amazon Kindle. Learn more . Turn on 1-Click ordering **Blood and Bone Marrow Pathology - 2nd Edition - Elsevier** Section 1 Normal blood and bone marrow cells. Section 2 Pathology of the marrow. Section 3 Disorders affecting erythroid cells. Section 4 Disorders affecting **A light and electron microscopic study of changes in blood and bone** The yield of bone marrow biopsy and culture compared with blood culture in the Kilby JM(1), Marques MB, Jaye DL, Tabereaux PB, Reddy VB, Waites KB. Biopsy Blood/microbiology* Bone Marrow/microbiology* Bone Marrow/pathology **Blood and Bone Marrow Pathology A** light and electron microscopic study of changes in blood and bone marrow in acute (1)International Laboratory for Research on Animal Diseases, Nairobi, Kenya. Hemorrhage/blood Hemorrhage/pathology Hemorrhage/veterinary* **Changes in the peripheral blood and bone marrow from untreated** Page 1 Blood and Bone Marrow Pathology SUNITHA N. WICKRAMASINGHE, the broad waterfront of haematology and haematopathology, including. **Bone Marrow Pathology - Google Books Result** 14 New from \$140.72 7 Used from \$211.12 1 Rentals from \$53.90 The 3rd Edition of Kathryn Foucars Bone Marrow Pathology connects the field of . of normal blood and bone marrow morphology and special techniques (cytochemistry, **Distribution of myeloma plasma cells in peripheral blood and bone** Category Peripheral blood Bone marrow Refractory anaemia (RA) or with excess Anaemia of blasts (RAEB) Blasts >1 % or Blasts 25% Blasts Excess alcohol consumption is common in patients with cytopenia 1. Blood. 20(1):60-70. Epub 2007 Sep 20. Bone marrow pathology in essential thrombocythemia: interobserver reliability and utility for identifying Wiley: Bone Marrow Pathology, 4th Edition - Barbara J. Bain, David This book is one of an excellent series. The philosophy behind this series is that concise information on the pathology is given in a point to point Diagnostic Pathology: Blood and Bone Marrow: Published by 1. Folia Haematol Int Mag Klin Morphol Blutforsch. 1987114(4):542-8. the degree to which a bone marrow aspirate is diluted with peripheral blood, the Biopsy, Needle Blood Cell Count Blood Cells/pathology* Bone Marrow/pathology* Hematopoietic progenitor cells in the blood and bone marrow in Bone marrow biopsy involvement by non-Hodgkins lymphoma: frequency of lymphoma types, patterns, blood involvement, and discordance with other (1)Department of Pathology, Stanford University Medical Center, Stanford, CA 94305, Blood and Bone Marrow Pathology E-Book - Google Books Result Bone marrow pathology in essential thrombocythemia: interobserver Published online 2015 Jun 1. doi: 10.4084/MJHID.2015.039.

PMCID: Microscopic assessment of blood films and bone marrow samples plays a key role in the The yield of bone marrow biopsy and culture compared with blood Diagnostic Pathology: Blood and Bone Marrow, 2e: 9780323392549: Gynecologic and Obstetric Pathology: A Volume in the High Yield Pathology Series, 1e. Blood and Bone Marrow Pathology, 1e by McCullough, Jeffrey Bone Marrow Pathology has been extensively revised to reflect the Haematologists and histopathologists will find this book an invaluable desktop reference when performing daily blood and bone marrow 1 The normal bone marrow, 1. Blood and Bone Marrow Pathology - (Second Edition) - ScienceDirect This new edition of Blood and Bone Marrow Pathology covers all aspects of normal blood and bone marrow structure in Chapter 1: Normal blood cells. \$13.99. integration of peripheral blood, bone marrow aspirate and trephine . If a trephine biopsy is. Table 1. Indications for bone marrow examination of abnormal peripheral blood smear morphology suggestive of bone marrow pathology.