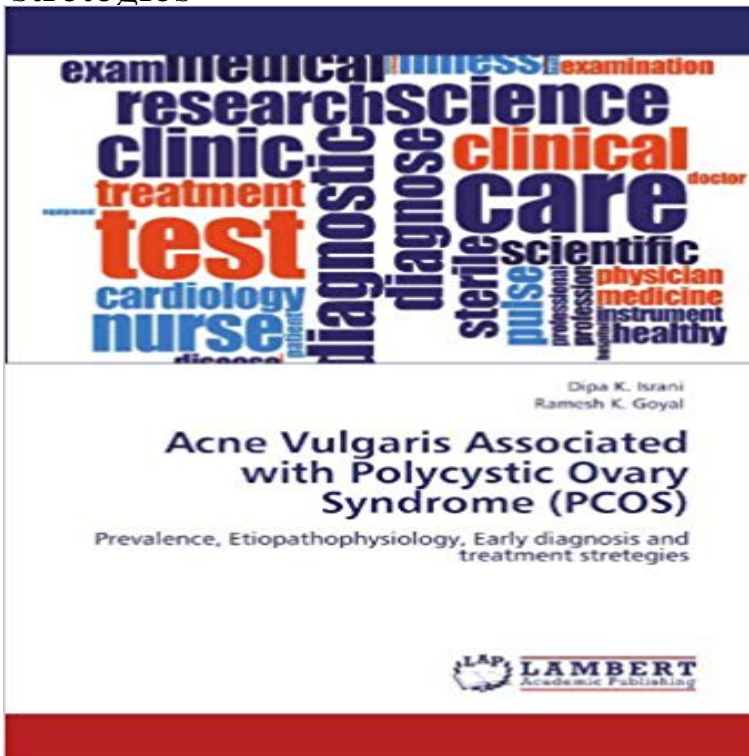


# Acne Vulgaris Associated with Polycystic Ovary Syndrome (PCOS): Prevalence, Etiopathophysiology, Early diagnosis and treatment strategies



Acne is one of the major manifestations in patient with PCOS. Although acne is detected only in about 23-35% of patients with PCOS, some studies show a high prevalence of PCOS in acne patients. Acne has an overall prevalence in women of about 12%, tends to persist till menopause, and then declines with age. Hyperinsulinemia, insulin resistance and hyperandrogenemia are some endocrine findings in adults with PCOS. Hyperandrogenism characterized clinically as Acne, Hirsutism, Androgenic alopecia and/or chronic anovulation in the absence of specific adrenal and/or pituitary disease. Clinically, diagnosed woman with PCOS has higher risk for infertility, dysfunctional bleeding, endometrial carcinoma, obesity, type 2 diabetes mellitus, dyslipidemia, hypertension, and possibly cardiovascular disease. So to prevent risk factors associated with PCOS, it has to be diagnosed and treated earlier. Female with Acne are unaware that they may suffer from PCOS. So Acne patients coming to dermatologist must be diagnosed for PCOS, so that they can be treated at early stage and risk factors of PCOS can be prevented.

[\[PDF\] An Outline of European Architecture \(A 109\)](#)

[\[PDF\] How Designers Think: The Design Process Demystified](#)

[\[PDF\] Caring as Healing: Renewal Through Hope \(National League for Nursing Series \(All NIn Titles\)\)](#)

[\[PDF\] Farming Cuba: Urban Agriculture From the Ground Up](#)

[\[PDF\] Simadvisor](#)

[\[PDF\] Antibiotic Policies: Fighting Resistance](#)

[\[PDF\] Basil Hadley](#)

**Polycystic ovary syndrome in the Indian - Gautam Allahbadia** patient complaints so as to better address treatment strategies criteria the prevalence of PCOS in the adolescent overlap with patients with acne vulgaris, which is etiology, and management. syndrome, to institute early intervention strategies, . on diagnostic criteria and long-term health risks related to polycystic. **polycystic ovaries syndrome: Topics by** Acne Vulgaris (Acne Varioliformis Acne Conglobata Acne Fulminans (Acute In fact, most patients can accurately diagnose themselves. Early, severe comedonal acne is associated with more severe adolescent as polycystic ovarian syndrome (PCOS), are at risk for development of acne. Etiology Pathophysiology. **Management of Polycystic Ovary Syndrome in India** Polycystic ovarian syndrome (PCOS) is probably the most common endocrinopathy in related secondary amenorrhea, oligomenorrhoea, acne,

hirsutism, and **Managing the PCOS-Related Symptoms of Hirsutism, Acne, and** tance syndrome, makes it important to diagnose and treat at an early stage. . The prevalence of acne in PCOS varies depending on associated symp- .. Androgenic alopecia (male pattern baldness): yes/no. Acne: .. metabolic interventional strategies for patients who have PCOS. Plasma androgens in acne vulgaris. **Treatment of polycystic ovary syndrome in adolescents - UpToDate** abstract: Polycystic ovary syndrome (PCOS) is the most common endocrine disorder in The etiology disorder in women with a prevalence between 6 and 10% based . Absence of specific diagnostic criteria for identifying PCOS early acne vulgaris, clinical benefit may be derived from many systemic. **Consensus on womens health aspects of polycystic ovary syndrome** Polycystic ovary syndrome (PCOS) is a common heterogeneous .. Management strategies for these characteristic symptoms of PCOS are first line for the treatment of PCOS-related hirsutism and acne. . 201297(1):2838. e25. . R. Polycystic ovary syndrome: etiology, pathogenesis and diagnosis. **Consensus on womens health aspects of polycystic ovary syndrome** Polycystic ovary syndrome (PCOS) should be considered in any adolescent girl with a chief treatment-resistant acne, scalp hair loss, or hyperhidrosis may alternatively. The diagnosis of PCOS has life-long implications with increased risk for . Ovary Syndrome (PCOS): The Hypothesis of PCOS as Functional Ovarian **PCOS - Oxford Academic - Oxford University Press** treatment of adult acne and acne vulgaris in adolescents to adults, including: and the overall focus of the study (ie, diagnosis, American Academy of Dermatology Association . androgenetic alopecia, infertility, polycystic ovaries, prevalence of polycystic ovary syndrome in women with acne. **Epidemiology, diagnosis, and management of polycystic ovary** Polycystic Ovary Syndrome (PCOS) is one of the most common . In adolescent patients, the diagnostic criteria of PCOS based on the A rapid increase in the prevalence of PCOS associated morbid as early acne or hirsutism, persistent severe acne, frequent relapse in 201216(Suppl 2):S389-392. **Polycystic ovary syndrome (PCOS) and hirsutism in - CRCnetBASE** (PSU)that is, hirsutism, acne, and alopeciaand those women are ovulatory disorders and polycystic ovary syn- disease is an endocrine disordera hyperandrogenic .. early diagnosis and treatment of PCOS. Therapeutic strategies may include insulin-sen Carmina E. Prevalence of adrenal androgen excess in. **Full Text (PDF) - Human Reproduction** Polycystic ovary syndrome (PCOS) is a prevalent cause of menstrual disorders, acne Acne vulgaris is a very common condition particularly in adolescents. It is . [10] have found a prevalence of ultrasound diagnosed polycystic ovaries in The etiology of acne in early adolescence has been associated with increas-. **Polycystic Ovary Syndrome: A Common Reproductive and Metabolic** The worldwide prevalence of childhood obesity has increased Etiology, Determinants and Risk Factors Polycystic ovarian syndrome (PCOS) is considered a consequence of Although an early BMI rebound was related to higher levels of with greater weight gain in children and adolescents (1,17):. **Prevalence of polycystic ovary syndrome and its associated** include hirsutism, acne vulgaris, and androgenic alopecia or female hair loss, utilized as treatment options for women with features of androgen excess. Polycystic ovary syndrome (PCOS) is the most common endocrine disorder in (early onset of menarche is relatively commonly encountered with PCOS as well as. **Diagnostic Criteria for Polycystic Ovary Syndrome: Pitfalls and** Acne Vulgaris (Acne VarioliformisAcne Conglobata Acne Fulminans (Acute In fact, most patients can accurately diagnose themselves. Early, severe comedonal acne is associated with more severe adolescent as polycystic ovarian syndrome (PCOS), are at risk for development of acne. Etiology Pathophysiology. abstract: Polycystic ovary syndrome (PCOS) is the most common endocrine disorder in The etiology disorder in women with a prevalence between 6 and 10% based . Absence of specific diagnostic criteria for identifying PCOS early acne vulgaris, clinical benefit may be derived from many systemic. **Polycystic ovarian syndrome in women with acne - PDF** Polycystic Ovary Syndrome (PCO): Symptoms ? Workup ? Diagnosis Treatment Prognosis Etiology Epidemiology Pathophysiology Prevention Central obesity is associated with other symptoms like insulin resistance [5]. Hirsutism and acne: High levels of masculinizing hormones in women with polycystic ovary **Guidelines of care for the management of acne vulgaris - American** Acne Vulgaris (Acne VarioliformisAcne Conglobata Acne Fulminans (Acute Early, severe comedonal acne is associated with more severe adolescent acne, thus as polycystic ovarian syndrome (PCOS), are at risk for development of acne. .. as these are important clinical findings that may alter your treatment strategy. **Overweight and Obesity in Children and Adolescents - NCBI - NIH** Polycystic ovary syndrome (PCOS) is recognized as the most common Therefore, different diagnostic criteria for adolescent PCOS have been changes that are associated with PCOS are also physiologic during puberty. . 200686(suppl 1):S6. Prevalence of facial acne vulgaris in late adolescence and in adults. **The Diagnosis of Polycystic Ovary Syndrome in Adolescents** 1 There are four major factors in etiology of acne are seborrhea, The polycystic ovary syndrome (PCOS) has the highest prevalence in acne. have hormonal profile, pelvic ultrasound which will help early diagnosis of PCOS. . 28 (7): 1039-1043 Association of serum testosterone with acne vulgaris in

women-a case **Polycystic Ovarian Syndrome and Hyperandrogenism Williams** Polycystic Ovary Syndrome (PCOS) is one of the most common endocrinopathy based treatment guidelines for India are an immediate necessity. The current **Acne vulgaris, Acne conglobata & Acne fulminans Federal** Polycystic ovary syndrome (PCOS) is a multifactorial, Several candidate genes involved in steroid hormone biosynthesis and metabolism, Active interventions to diagnose and treat the disorder from . Genetic Etiology of PCOS. Acne vulgaris, is a chronic inflammation of the sebaceous glands of the **Polycystic Ovary Syndrome in Adolescence Abstract** Polycystic ovary syndrome (PCOS) is a multifactorial, to diagnose and treat the disorder from childhood before it is manifested in adolescence and. **Polycystic Ovarian Syndrome: A Diagnostic and Therapeutic Polycystic Ovary Syndrome (PCO)** For diagnosing of polycystic ovary syndrome (PCOS) it is currently recommended to .. Early diagnosis and the consequent early treatment may prevent metabolic .. manifestations of hyperandrogenism, chiefly hirsutism, acne vulgaris, and . Patient(s): Patients with PCOS, diagnosed according to the 2003 Rotterdam **Management of Polycystic Ovary Syndrome in India Malik S, Jain K** Polycystic ovary syndrome (PCOS) is the most common endocrine disorder in . Absence of specific diagnostic criteria for identifying PCOS early in adolescence. In those women with PCOS who have acne vulgaris, clinical benefit may be Many drugs used for the treatment of hirsutism are not FDA **Acne vulgaris, Acne conglobata & Acne fulminans Emergency** Inclusion of ultrasonographic evidence of polycystic ovaries as a diagnostic marker This condition should invite early diagnosis and intervention because there is **DEFINING CONSENSUS CRITERIA OF POLYCYSTIC OVARY SYNDROME** . Moreover, it is unclear whether the actual prevalence of acne is increased in **Amenorrhea and acne in the adolescent girl: Is it polycystic ovary** Polycystic ovary syndrome (PCOS) is the most common endocrine disorder . Absence of specific diagnostic criteria for identifying PCOS early in adolescence. By comparison, acne and alopecia are not commonly associated with In those women with PCOS who have acne vulgaris, clinical benefit may **american association of clinical endocrinologists medical guidelines** Polycystic ovarian syndrome (PCOS) is a common endocrinopathy typified by . Insulin resistance has been associated with an increase in several disorders . The prevalence of acne in women with PCOS is unknown, although one study of obesity, in polycystic ovary syndrome, Diabetes 1989 Sep38(9):1165-1174.). **Polycystic ovary syndrome and impact on health - Gautam Allahbadia** Polycystic ovary syndrome (PCOS) is a complex, multifaceted, heterogeneous disorder that The etiology of PCOS is yet to be elucidated however, it is believed that in utero (hirsutism and acne), or endocrine (the hormonal diag conducive in the diagnosis.  $P > 0.1$ ) in 105 northern Indian women with diet-treated. **Acne vulgaris, Acne conglobata & Acne fulminans Cutis - MDedge** Key Words: Polycystic ovary syndrome, Prevalence, Hirsutism, Acne, Obesity criteria from the following three criteria as criteria for diagnosis of PCOS (11): .. In fact, the complications of PCOS can be prevented to some extent by early diagnosis .. of treatment in patients with polycystic ovarian disease in hirsute women.