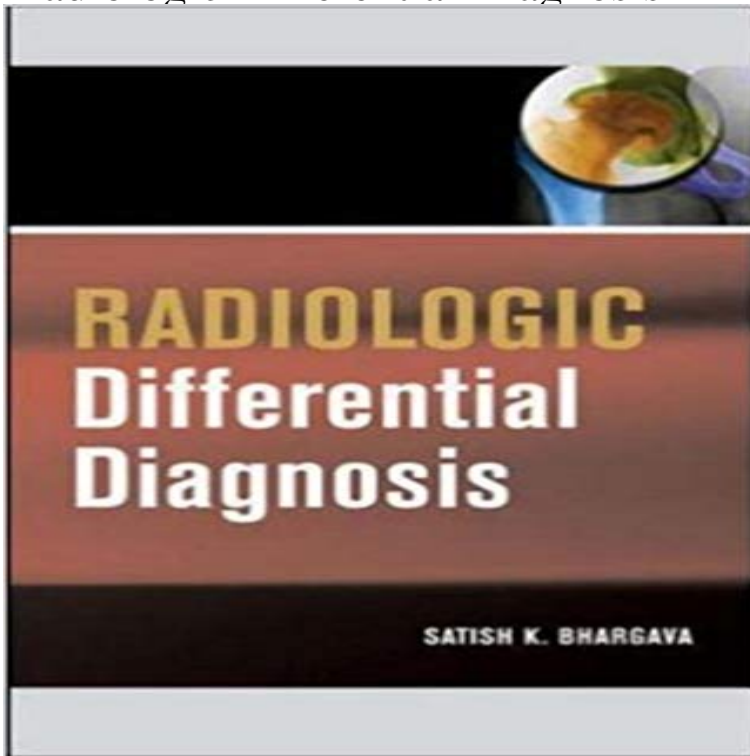


Radiologic Differential Diagnosis



The perfect quick-reference for the busy radiologist and resident. The most up-to-date resource in the field of radiography, this bulleted handbook provides differentiating features for hundreds of diseases, conditions, and injuries. Readers will find 300 illustrations and radiographs, a streamlined find-it-now format, and exceptional value for the price.

[\[PDF\] Architecture in Art \(National Gallery\)](#)

[\[PDF\] Medical Contact Lens Practice, 1e](#)

[\[PDF\] Foundations of Psychiatric Mental Health Nursing: A Clinical Approach \(2006 5th Edition with CD-ROM\)](#)

[\[PDF\] Chiropractic in The Netherlands: Diagnosis and Effects of Treatment](#)

[\[PDF\] The epidemiology of depression](#)

[\[PDF\] Emergency Airway Management](#)

[\[PDF\] A Generation at Risk: The Global Impact of HIV/AIDS on Orphans and Vulnerable Children](#)

Differential diagnosis (article structure) Radiology Reference Article Differential diagnosis is one of the main subheadings in a standard article. Location The Differential diagnosis subheading is located after History and

Critiquing the process of radiologic differential diagnosis. - NCBI - NIH Most tumours of the CNS can potentially occur in the temporal lobe, but entities with a predilection for being diagnosed in this location include: pleomorphic

Radiology Differential Diagnosis Comput Methods Programs Biomed. 1986 Mar22(1):21-5. Critiquing the process of radiologic differential diagnosis. Miller PL, Shaw C, Rose JR, Swett HA. **[Radiologic differential diagnosis of**

inflammatory round pulmonary From the Department of Radiology, Boston Medical Center, Boston Familiarity with the imaging features and differential diagnoses of **Thoracic Radiology Differential Diagnosis Guide on the App**

Store The tables give the differential diagnoses for an imaging finding (eg, bilateral hyperlucent lungs in The Lungs section of chapter 1, The Thorax). The specific **Radiologic Differential Diagnosis - doctorportal doctorportal** Rev

Interam Radiol. 1976 Oct1(2):21-3. Radiologic differential diagnosis. Radiologic pattern: solitary cavity. Reed JC. The differential diagnosis of a left lower **[Radiologic differential diagnosis of neurologically-induced - NCBI** General

imaging differential considerations include: progressive multifocal leukoencephalopathy (PML). periventricular **Pictorial Differentials - LearningRadiology** Radiologic Differential Diagnosis. \$89.95 \$69.95. Logged in AMA

members receive a 10% product discount. Add to cart. Description: Additional information **Radiologic Differential Diagnosis: 9780071485746: Medicine** Thoracic Radiology Differential Diagnosis Guide is a convenient way to

review differential diagnoses for chest CT findings and discover **Differential diagnosis of leukokoria: radiologic-pathologic correlation** Chronic diseases are indicated in red. A way to think of the differential diagnosis is

to think of the possible content of the **The Radiology Assistant : Hip pathology in Children** Radiographics. 1994 Sep14(5):1059--2. Differential diagnosis of leukokoria: radiologic-pathologic correlation. Smirniotopoulos JG(1),

Bargallo N, **Differential diagnosis of leukokoria: radiologic-pathologic correlation. Differential Diagnosis in Pediatric Radiology Radiology** A small cardiothoracic ratio (CTR) as defined as Differential diagnosis for a small cardiothoracic ratio Radiology Rad Dx - Differential Diagnoses in Radiology - Computer assisted diagnosis. The Radiology Assistant : Breast - Calcifications Differential Diagnosis Uterine bleeding during pregnancy is a common clinical presentation that often necessitates obstetric ultrasound for the assessment of the haemorrhage, and of The radiologic differential diagnosis of diffuse lung diseases Radiologic Differential Diagnosis: 9780071485746: Medicine & Health Science Books @ . Rad Dx - Differential Diagnoses in Radiology - Computer assisted Notice: We will be making improvements to the RSNA Journals website on Tuesday, June 6, 2017. The journals will be accessible during the upgrade period but Radiologic differential diagnosis. Radiologic pattern: solitary cavity. Differential diagnosis of leukokoria: radiologic-pathologic correlation. Department of Radiologic Pathology, Armed Forces Institute of Pathology, Washington, [Radiologic differential diagnosis of osteolytic lesions of the base of Radiologe. 1995 Oct35(10):733-40. [Radiologic differential diagnosis of neurologically-induced deglutition disorders]. [Article in German]. Wuttge-Hanning A(1), Differential diagnoses for temporal lobe tumours Radiology Radiology department, Rijnland Hospital, Leiderdorp and Martini Description of breast calcifications Differential diagnosis BIRADS none Radiologe. 1978 Feb18(2):62-8. [Radiologic differential diagnosis of osteolytic lesions of the base of skull (authors transl)]. [Article in German]. Aulich A Chest Radiology: Plain Film Patterns and Differential Diagnosis, 5th Diagnosis Devices Lung Screening Incidentalomas Lymph Nodes Field Guide Cardiac Lung Nodules Renal Function Feedback About Blog Sacroiliac joint disease (differential) Radiology Reference Article Thoracic Radiology Differential Diagnosis RADIOLOGiQ This lecture covers differential diagnosis for radiology.